

Dong-Won Lee  
Young-Shill Choi  
Kwang-Ho Park  
Chang-Sung Kim  
Ik-Sang Moon

# Effect of microthread on the maintenance of marginal bone level: a 3-year prospective study

## Authors' affiliations:

Dong-Won Lee, Young-Shill Choi, Ik-Sang Moon,  
Department of Periodontology, Yongdong Severance  
Hospital, College of Dentistry, Yonsei University,  
Seoul, Korea

Kwang-Ho Park, Department of Oral &  
Maxillofacial surgery, Yongdong Severance Hospital,  
College of Dentistry, Yonsei University, Seoul,  
Korea

Chang-Sung Kim, Department of Periodontology,  
College of Dentistry, Yonsei University, Seoul,  
Korea.

## Correspondence to:

Ik-Sang Moon  
Department of Periodontology  
Yongdong Severance Hospital  
College of Dentistry  
Yonsei University  
Seoul  
Korea  
Tel.: +82 2 2019 3565  
Fax: +82 2 2019 9082  
e-mail: ismoon@yumc.yonsei.ac.kr

**Key words:** marginal bone level, microthread, prospective study, radiographic image

## Abstract

**Objectives:** The purpose of the present study was to evaluate the long-term effect of the microthread on the maintenance of marginal bone level.

**Material and methods:** Seventeen patients were selected and two types of Astra Tech implants were installed, with the Microthread™ on the coronal portion of the fixture [Astra Tech Single Tooth Implant (ST)] or without the Microthread™ [Astra Tech TiOblast Implant (TB)]. ST and TB were installed adjacent to each other within the same partially edentulous sites and marginal bone loss was evaluated by radiographic image. The marginal bone-level alteration of the each fixture after prosthesis insertion was analyzed.

**Results:** The marginal bone loss of ST and TB differed significantly during the observation period ( $P < 0.01$ ). Marginal bone levels of both ST and TB were stabilized after 1 year of lading.

**Conclusions:** The Microthread™ might have an effect in maintaining the marginal bone loss against loading.

The esthetically supreme implant therapy relies largely on the topography and dimension of the surrounding soft tissue, that is, peri-implant mucosa. However, the height of the supracrestal soft tissue portion is highly relevant to the level of bony support around the fixture (Chang et al. 1999). Therefore, studies on the changes of the marginal bone around dental implants have significance not only for the functional maintenance but also for the esthetic success of the dental implant.

Albrektsson et al. (1986) established the success criteria that the marginal bone-level change in the first year should be  $< 1-1.5$  mm, and ongoing annual bone loss should be  $< 0.2$  mm. Adell et al. (1981) reported a bone loss of 1.2 mm in the Brånemark System® for the first year in his 15-year study. Also, correlations were

found between the amount of bone loss after 12 months and the length of the machined surface for various implant systems, thus relating bone loss and the level of the 'first thread' (Jung et al. 1996).

It was theoretically analogized that a conical implant-abutment interface brought about a decrease in the peak bone-implant interfacial shear stress as compared with a flat top interface (Hansson 1999). However, in studies on the marginal bone loss of the Astra Tech implant, bone loss varied from 0.05 to 0.6 mm during 1 year of loading. Thus, relatively uneven degrees of bone loss measurements were reported in the studies, that dealt with marginal bone loss of Astra Tech implants (Norton 1998; Palmer et al. 2000; Puchades-Roman et al. 2000; Engquist et al. 2002).

## Date:

Accepted 13 March 2006

## To cite this article:

Lee D-W, Choi Y-S, Park K-H, Kim C-S, Moon I-S.  
Effect of microthread on the maintenance of marginal  
bone level: a 3-year prospective study.  
*Clin. Oral Impl. Res.*  
doi: 10.1111/j.1600-0501.2007.01302.x

**Table 1. Distribution of the installed implants according to jaw and fixture**

Jaw	Fixture	Placed site														Total	
		7	6	5	4	3	2	1	1	2	3	4	5	6	7		
Maxilla	ST	3	2	2								1	1	1	1	11	
	TB		4	2	1							1	2	1		11	
Mandible	ST	1	1							1					1	2	6
	TB	1	1				1								2	1	6
Total		5	8	4	1		1			1		1	2	3	5	4	34

ST, Astra Tech Single Tooth implant; TB, Astra Tech TiOblast implant.

It was proposed that bone-retention elements such as microthread and rough surface at the implant neck might help stabilize the marginal bone (Hansson 1999). As the Astra Tech implants were available in two types, with and without a microthread, this might explain the uneven bone loss measurements among Astra Tech implant in past studies.

The aim of the present prospective clinical study was to evaluate the long-term effect of the Microthread™ on the marginal bone loss at the fixture.

**Material and methods**

**Patient selection**

Subjects of this study were selected from patients who received periodontal therapy and implant surgeries at the department of Periodontology at the Yongdong Severance Hospital (College of Dentistry, Yonsei University, Seoul, Korea) from January 2001 to June 2001. The study protocol was approved by the Yonsei University Ethics Committee. Informed consent was obtained from all subjects.

The patients included in this study showed good general health at the time of selection. After receiving initial therapy including oral hygiene instruction, scaling and root planning, patients had undergone corrective therapy including extraction and

periodontal surgery. Implantation was performed after patients had shown good self-performed plaque control.

In total, nine males and eight females participated in the present study with a mean age of 53.3 years (range 31–76).

**Implants**

The coronal portion of Astra Tech Single Tooth Implant (ST) is tapered with the Microthread™. The apical part of the fixture has a diameter of 3.5 and 4 mm, which increases at the marginal collar, thus making the coronal diameter 4.5 and 5 mm. On the other hand, Astra Tech TiOblast Implant (TB) has a cylindrical shape, without the Microthread™, and diameters of 3.5 and 4 mm were used. However, both ST and TB shared the same surface texture, achieved through a titanium grit-blasting technique (Gotfredsen et al. 1992).

**Treatment procedure**

At the same edentulous area of each patient, one fixture of each implant type was installed in a randomized order (Table 1). After a healing period of 3 months in the mandible and 6 months in the maxilla, a second surgery was performed. Three weeks after the second surgery, the prosthesis (2-unit bridge) was delivered. The patients were recalled every 3 months for

thorough professional plaque control and repeated oral hygiene education.

In total, 34 Astra Tech Dental Implants were installed (22 in the maxilla and 12 in the mandible).

**Follow-up parameters**

Clinical examination was conducted every 3 months after prosthesis delivery. The appropriate number of intra-oral radiographs for each subject was taken at baseline (prosthesis delivery), 1, 2, and 3-year follow-ups.

The following clinical variables were recorded at the baseline examination (delivery of the prosthesis) and at the annual follow-ups (Engquist et al. 2002).

- Pain from implant regions;
- Implant stability;
- Gingival inflammation; and
- Suprastructure complications.

**Radiographic examination**

A periapical radiograph (Kodak Insight, film speed F, Rochester, NY, USA) was taken (70 KVp, 10 mA, Yoshida REX 601, Tokyo, Japan) (Wyatt et al. 2001) using the parallel cone technique with an XCP device (XCP Kit, Rinn, Elgin, IL, USA). All films were developed using the same automatic processor (Periomat, Dürr Dental, Bietigheim-Bissingen, Germany) following the manufacturer’s instructions (Fig. 1).

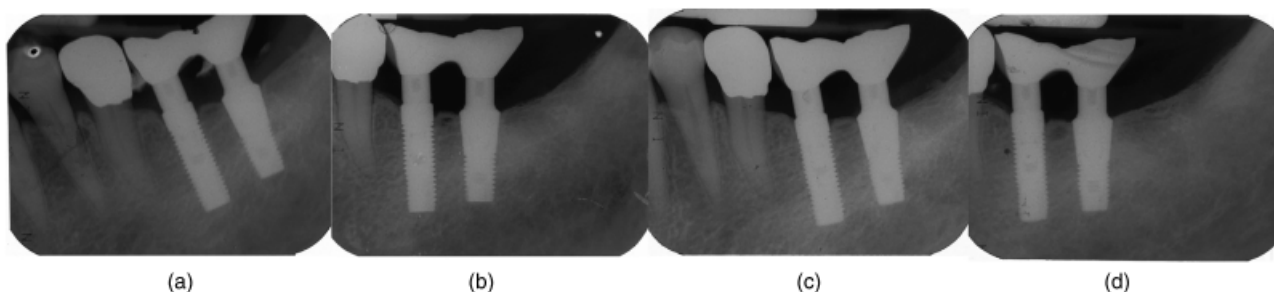


Fig. 1. Intra-oral radiographs of implants (a: baseline; b: 1-year; c: 2-year; d: 3-year follow-up).




Fig. 2. Schematic presentation of measurements of site and reference point, ST, Astra Tech Single Tooth implant; TB, Astra Tech TiOblast implant.

The radiographs were scanned (UMAX, Astra 4000U, Seoul, Korea) at 600 dpi, 256 gray scale.

**Measurement of marginal bone-level change**

After digitization, all files were transferred to a personal computer (Processor, Intel Pentium 2.4 GHz, Santa Clara, CA, USA; operating system, Windows 2000, Redmond, WA, USA) and examined using the same monitor (Flatron LCD, LG, Seoul, Korea), which was set to a resolution of 1024 × 768 pixels. During the

computer-assisted radiographic measurements, the room was darkened (Lee et al. 2005).

The marginal bone-level measurement was made from the reference point to the lowest observed point of contact of the marginal bone with the fixture. The reference point of the fixture (ST, TB) was the border between the titanium oxide-blasted surface and the machined surface of the fixture (Fig. 2). Calibration was performed with known fixture length (Brägger et al. 1998). The distance was measured to the nearest 0.01 mm with UTHSCSA Image Tool (Version 3.00, The University of Texas Health Science Center in San Antonio). Only the amount of vertical bone loss was measured. Thus, in case of coronal bone gain, bone loss was considered to be zero. The amounts of bone loss on the mesial and distal sides of the implants were measured and the average value was used.

**Statistical analysis**

The hypotheses to be tested were:

1. There would be no difference between the marginal bone loss of ST and TB during the examination period.
2. The amount of bone loss during each time interval (baseline to 1 year, 1–2 years and 2–3 years) would be similar.

Wilcoxon’s signed-rank test was used to test whether differences in marginal bone loss existed between groups ST and TB.

Also, to detect the time of stabilization of the marginal bone, the additional bone loss of each time interval (baseline to 1 year, 1–2 years and 2–3 years) was compared with the Wilcoxon’s signed-rank test. The value was deemed significant if the *P*-value was lower than 0.01.

**Results**

**Clinical examination**

No remarkable complications were found during the observation period. No patient suffered from pain, or mobility on implants was not detected. Also, there were no prosthetic complications.

In one patient, a slight soft tissue inflammation was diagnosed at the 3-month follow-up after the prosthesis delivery. After a decontamination procedure, the soft tissue inflammation ceased.

**Marginal bone-level changes**

The marginal bone loss for each type of implant is illustrated in Table 2 and Fig. 3. The amount of peri-implant bone loss was significantly larger on TB than ST during the examination period (Table 3).

Additional amount of bone loss between each interval was compared on both ST and TB. ST showed 0.14 mm bone loss during the first year, which was a significantly higher bone loss than 0.07 and 0.03 mm during the second and third years, respectively. Also, TB showed 0.28 mm bone loss during the first year, which was a

**Table 2. Marginal bone loss of ST and TB**

Type of implant Subject/year	ST			TB		
	1	2	3	1	2	3
1	0.08	0.16	0.19	0.14	0.3	0.35
2	0.06	0.11	0.11	0.09	0.13	0.14
3	0.22	0.29	0.37	0.41	1.11	1.12
4	0	0.14	0.21	0.37	1.05	1.12
5	0.13	0.13	0.13	0.27	0.33	0.33
6	0.06	0.12	0.23	0.09	0.22	0.28
7	0.21	0.39	0.4	0.23	0.38	0.38
8	0.06	0.08	0.1	0.45	0.72	0.72
9	0.36	0.41	0.46	0.4	0.7	0.74
10	0.19	0.22	0.24	0.77	0.94	1.05
11	0.02	0.04	0.06	0.16	0.24	0.25
12	0.36	0.38	0.39	0.47	0.55	0.57
13	0.17	0.28	0.3	0.42	0.44	0.44
14	0	0.02	0.02	0.12	0.13	0.13
15	0.1	0.14	0.2	0.01	0.09	0.16
16	0.15	0.3	0.31	0.14	0.26	0.28
17	0.23	0.31	0.35	0.21	0.55	0.55

ST, Astra Tech Single Tooth implant; TB, Astra Tech TiOblast implant.

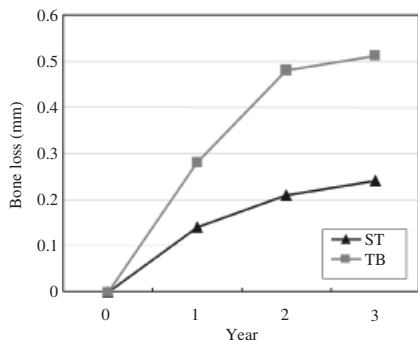


Fig. 3. Marginal bone loss between two different implant systems. ST, Astra Tech Single Tooth implant; TB, Astra Tech TiOblast implant.

significantly higher bone loss than 0.2 mm and 0.03 mm during the second and third years (Tables 4 and 5).

### Discussion

The purpose of the present study was to evaluate the long-term effect of the Microthread™ on the maintenance of marginal bone level. Previously published retrospective studies had a difficulty in matching the individual load to each fixture to be tested. To overcome this, fixtures of different types were aligned adjacent to each other and connected. Oral hygiene care was also carried out thoroughly to minimize the possible effect of peri-implantitis.

The bone loss measurement of ST and TB was within the success criteria established by Albrektsson et al. (1986). However, marginal bone loss of ST was significantly lower than the TB (Table 3) ( $P < 0.01$ ). Considering the smaller marginal bone changes at the ST, it could have contributed to the effect of the Microthread™ in maintaining the bone level. Many reports have emphasized the influence of surface structure on bone-to-implant interface against the marginal bone loss. Wilke et al. (1990) drew attention to increased resistance to interfacial shear strength between implant and bone, when the surface of the implant was in some way roughed, and stated that the morphology and dimensions of the surface roughness may also influence the implant's 'holding power.' Hansson (1999) also supported these findings by utilizing mathematical model on 3D and axisymmetric finite element analysis to determine the ideal rough

Table 3. Marginal bone-level changes between baseline and at 1-, 2- and 3-year follow-ups (Mean, SEM)

	Baseline–1 year	Baseline–2 years	Baseline–3 years
ST	0.14 ± 0.11	0.21 ± 0.13	0.24 ± 0.13
TB	0.28 ± 0.19	0.48 ± 0.32	0.51 ± 0.33
P-value	0.002*	0.001*	0.001*

ST, Astra Tech Single Tooth implant; TB, Astra Tech TiOblast implant.  
Level of significance (\* $P < 0.01$ ).

Table 4. Marginal bone loss changes at each time interval between two different implant systems

	Baseline–1 year	1–2 years	2–3 years
ST	0.14 ± 0.11	0.07 ± 0.05	0.03 ± 0.03
TB	0.28 ± 0.19	0.20 ± 0.21	0.03 ± 0.03

ST, Astra Tech Single Tooth implant; TB, Astra Tech TiOblast implant.

Table 5. Statistical comparison of bone loss during the time interval (baseline to 1 year, 1–2 years and 2–3 years) in both systems (\* $P < 0.01$ )

	Baseline	1 year	2 years	3 years
ST		0.001*	0.013	0.03
TB	0*	0.155	0.03	

ST, Astra Tech Single Tooth implant; TB, Astra Tech TiOblast implant.

surface. He hypothesized that the surface roughness or the retentive elements like the microthread could increase the resistance of marginal bone against the bone loss by the interlocking force between the implant surface and the crestal bone. Furthermore, from the literature review on the crestal bone loss around dental implants, the role of the first thread was transform the shear force between the implants and crestal bone into the compressive force to which bone is the most resistant (Oh et al. 2002). Jung et al. (1996) also reported bone loss to the level of the first thread in other implant systems such as 3i and Steri-Oss.

Other than the Microthread™, another difference existed between TB and ST, which could affect the result in this study. The coronal portion of ST is tapered, thus providing a larger diameter at the coronal side of the fixture. However, a study using modified TB and ST, which both had the microthread, showed no differences in bone-to-implant contact ratio and marginal

bone level. Thus, the possible effect of a divergent crest module design on the marginal bone loss was investigated and no correlation was found (Rasmusson et al. 2001).

ST showed significantly larger bone loss during the first year of loading than those during the second and third year of loading. This indicated that a steady bone level had been established after the 1-year examination. A similar pattern of bone loss was observed on the TB. The marginal bone loss of dental implants related to the occlusal force reached steady state after a few years by establishing an equilibrium between the occlusal load and marginal bone loss (Adell et al. 1986). From these results, the Microthread™ on the coronal region of fixture may reduce the crestal bone loss, but contribution to the early biomechanical adaptation against loading could not be verified.

The drawback of the present study was the use of radiographic analysis, which may lead to a false diagnosis when analyzing

small peri-implant bone-level change (Brägger et al. 1998). The accuracy of using inter-thread distance as an internal reference was reported to be within 0.3 mm (Hollender & Rockler 1980). Further study using more sophisticated methods, such as histologic specimen analysis, in order to verify the results of the present study is necessary.

Also, different patterns of bone resorption patterns were observed in patients 3, 4, 8 and 10. This might be due to the fact that all the patients had periodontitis. A recent study evaluated that the amount of peri-implant bone loss was related to the pre-treatment experience of loss of periodontal bone support (Hardt et al. 2002). All the patients enrolled in the present study received periodontal treatment before implant surgery. However, the degree of periodontal disease differed and was not considered in the statistical analysis, due to the limitation of the number of the patients.

Different design, especially with respect to design of the fixture–abutment junction, could lead to different dimensions of the biologic width (Hermann et al. 2001). Thus, comparison of the dimension of the peri-implant mucosa of ST and TB would be worth analyzing in the present study.

However, as the ST and TB shared an identical fixture–abutment junction (Conical Seal Design™), a difference in the design of the fixture mainly would not lead to distinctive features of the dimension of the biologic width.

The mechanical disruption of the mucosal barrier may influence marginal bone resorption (Abrahamsson et al. 1997). However, as the transmucosal abutment manipulation of the adjacent implants was identical, the possible influence of the dimension of peri-implant mucosa following abutment dis/reconnection would be diminished.

In conclusion, decreased marginal bone loss on ST might be due to the Microthread™ on the coronal side of the fixture. However, the effect of the Microthread™ on the early stabilization of the crestal bone level could not be verified. According to the study on the mechanical property of the bone (Guo 2001), bone is most resistant against the compressive strength and 30% less against the tensile strength and 65% less resistant against the shear strength. Therefore, to minimize the bone loss, the crestal module design, which can decrease the shear force on the crestal bone, is important. Further research on the microthread and other fixture designs is

needed to clarify the mechanism and the relationship between implant design and crestal bone loss.

**Acknowledgement:** This work was supported by the Yonsei University Research Fund of 2004.

#### 要旨

目的：本研究の目的は、辺縁骨レベルの維持に Microthread (マイクロスレッド)™ が及ぼす長期効果を評価することであった。材料と方法：患者 17 名を選択し、2 種類の Astra Tech インプラント (Astra Tech AB, Molndal, スウェーデン)、すなわちフィクスチャーの歯冠側部分にマイクロスレッド™が備わっているもの (Astra Tech Single Tooth Implant; ST)、またはマイクロスレッド™が備わっていないもの (Astra Tech TiOblast Implant; TB) を埋入した。ST と TB は同じ無歯顎部位に相互に隣接させて埋入し、辺縁骨の喪失を X 線像によって評価した。補綴物装着後に各フィクスチャーの辺縁骨レベルの変化を分析した。

結果：ST と TB の辺縁骨喪失は観察期間中に有意に異なっていた ( $p < 0.01$ )。ST と TB の辺縁骨レベルは荷重 1 年後に安定化した。

結論：マイクロスレッド™は荷重後の辺縁骨維持に有効でありうる。

## References

- Abrahamsson, I., Berglundh, T. & Lindhe, J. (1997) The mucosal barrier following abutment dis/reconnection. An experimental study in dogs. *Journal of Clinical Periodontology* **24**: 568–572.
- Adell, R., Lekholm, U., Rockler, B. & Brånemark, P.I. (1981) A 15-year study of osseointegrated implants in the treatment of the edentulous jaw. *International Journal of Oral Surgery* **10**: 387–416.
- Adell, R., Lekholm, U., Rockler, B., Brånemark, P.I., Lindhe, J., Eriksson, B. & Sbordone, L. (1986) Marginal tissue reactions at osseointegrated titanium fixtures (I). A 3-year longitudinal prospective study. *International Journal of Oral and Maxillofacial Surgery* **15**: 39–52.
- Albrektsson, T., Zarb, G., Worthington, P. & Eriksson, R.A. (1986) The long-term efficacy of currently used dental implants. A review and proposed criteria for success. *International Journal of Oral & Maxillofacial Implants* **1**: 11–25.
- Brägger, U., Häfeli, U., Huber, B., Hämmerle, C.H.F. & Lang, N.P. (1998) Evaluation of post-surgical crestal bone levels adjacent to non-submerged dental implants. *Clinical Oral Implants Research* **9**: 218–224.
- Chang, M., Wennström, J.L., Ödman, P. & Andersson, B. (1999) Implant supported single-tooth replacements compared to contralateral natural teeth. Crown and soft tissue dimensions. *Clinical Oral Implants Research* **10**: 185–194.
- Engquist, B., Åstrand, P., Dahlgren, S., Engquist, E., Feldmann, H. & Gröndahl, K. (2002) Marginal bone reaction to oral implants: a prospective comparative study of Astra Tech and Brånemark System implants. *Clinical Oral Implants Research* **13**: 30–37.
- Gotfredsen, K., Nimb, L., Hjörting-Hansen, E., Jensen, J.S. & Holmén, A. (1992) Histomorphometric and removal torque analysis for TiO<sub>2</sub>-blasted titanium implants. An experimental study on dogs. *Clinical Oral Implants Research* **3**: 77–84.
- Guo, X.E. (2001) Mechanical properties of cortical bone and cancellous bone tissue. In: Cowin, S.C., ed. *Bone Mechanics Handbook*, 1–23. Boca Raton: CRC Press.
- Hansson, S. (1999) The implant neck: smooth or provided with retention elements. A biomechanical approach. *Clinical Oral Implants Research* **10**: 394–405.
- Hardt, C.R.E., Gröndahl, K., Lekholm, U. & Wennström, J.L. (2002) Outcome of implant therapy in relation to experienced loss of periodontal bone support. A retrospective 5-year study. *Clinical Oral Implants Research* **13**: 488–494.
- Hermann, J.S., Buser, D., Schenk, R.K., Schoolfield, J.D. & Cochran, D.L. (2001) Biologic width around one- and two-piece titanium implants. A histometric evaluation of unloaded nonsubmerged and submerged implants in the canine mandible. *Clinical Oral Implants Research* **12**: 559–571.
- Hollender, L. & Rockler, B. (1980) Radiographic evaluation of osseointegrated implants of the jaws. Experimental study of the influence of radiographic techniques on the measurement of the relation between implant and bone. *Dentomaxillofacial Radiology* **9**: 91–95.
- Jung, Y.-C., Han, C.-H. & Lee, K.-W. (1996) A 1-year radiographic evaluation of marginal bone around dental implants. *International Journal of Oral & Maxillofacial Implants* **11**: 811–818.
- Lee, D.-W., Kim, C.-K., Park, K.-H., Cho, K.-S. & Moon, I.-S. (2005) Non-invasive method to measure the length of soft tissue from the top of papilla

- to the crestal bone. *Journal of Periodontology* **76**: 1311–1314.
- Norton, M. (1998) Marginal bone levels at single tooth implants with a conical fixture design. The influence of surface macro- and microstructure. *Clinical Oral Implants Research* **9**: 91–99.
- Oh, T.J., Yoon, J., Misch, C.E. & Wang, H.L. (2002) The Causes of early implant bone loss: myth or Science? *Journal of Periodontology* **73**: 322–333.
- Palmer, R.M., Palmer, P.J. & Smith, B.J. (2000) A 5-year prospective study of Astra single tooth implants. *Clinical Oral Implants Research* **11**: 179–182.
- Puchades-Roman, L., Palmer, R.M., Palmer, P.J., Howe, L.C, Ide, M. & Wilson, R.F. (2000) A clinical, radiographic, and microbiologic comparison of Astra Tech and Brånemark single tooth implants. *Clinical Implant Dentistry and Related Research* **2**: 78–84.
- Rasmusson, L., Kahnberg, K.-E. & Tan, A. (2001) Effects of implant design and surface on bone regeneration and implant stability: an experimental study in the dog mandible. *Clinical Implant Dentistry and Related Research* **3**: 2–8.
- Wilke, H.J., Claes, L. & Steinemann, S. (1990) The influence of various titanium surfaces on the interface shear strength between implants and bone. In: Heimke, G., Soltesz, U. & Lee, A.J.C., eds. *Clinical Implant Materials: Advances in Biomaterials*, 309–314. Amsterdam: Elsevier Science Publishers B.V.
- Wyatt, C.C.L., Bryant, S.R., Avivi-Arber, L., Chaytor, D.V. & Zarb, G.A. (2001) A computer-assisted measurement technique to assess bone proximal to oral implants on intraoral radiographs. *Clinical Oral Implants Research* **12**: 225–229.